

The Novel Use of Bipolar Radiofrequency Microneedling in the Treatment of Lichen Sclerosus

TRACY A. BLUSEWICZ, MD (FACOG)¹
GYNECOLOGY SPECIALIST

ROBERT D. MOORE, DO (FACOG, FPRMRS, FACS)^{2,3}
FEMALE PELVIC MEDICINE AND RECONSTRUCTIVE SURGERY
SPECIALIST

KATHERINE P. COLEY, MD (FACOG)¹
GYNECOLOGY SPECIALIST

JOHN R. MIKLOS, MD (FACOG, FPMRS)^{2,3}
FEMALE PELVIC MEDICINE AND RECONSTRUCTIVE
SURGERY SPECIALIST

¹ADVANCED WOMEN'S HEALTH CARE OF THE LOWCOUNTRY, PC, HILTON HEAD, SOUTH CAROLINA

²MIKLOS AND MOORE UROGYNECOLOGY, ATLANTA, GEORGIA

³BEVERLY HILLS, CALIFORNIA, DUBAI, UNITED ARAB EMIRATES

ABSTRACT

Introduction: Lichen sclerosus (LS) is a chronic, distressing, inflammatory process that has a huge impact on quality of life in women. Uncontrolled vulvar LS can lead to chronic symptoms of itching and pain and can lead to anatomic changes, scarring, and elevated risk of cancer. First-line therapy with corticosteroids is often not successful in controlling symptoms, especially over the long term. This is the first study to review the effects of bipolar radiofrequency (RF) with microneedling to treat the vaginal and vulvar symptoms of LS.

Materials and Methods: This retrospective study was initiated due to the recognition of improvement in vulvar skin condition and resolution of lichen sclerosus symptoms in patients who had already failed traditional treatment and underwent radio frequency with microneedling procedures of the vulva, perineum, and perianal regions. Patients were treated with three treatments of bipolar RF and bipolar RF with microneedling four to eight weeks apart. Patient questionnaires were used to assess improvement in the symptoms of LS including itching, tearing of tissue, changes in the appearance and color of tissue, and dryness of skin and mucosa.

Results: The data from the questionnaires showed a significant reduction or complete resolution in these symptoms, with 86% of the patients reporting either significant or complete resolution. In the case of itching, which is typically one of the most severe symptoms of LS, 91% of patients reported significant or complete resolution. 87% of patients reported symptom resolution lasting at least six months, with 39% of the patients having results lasting 12 months or more before recurrence. Recurrences can be retreated on an as-needed basis or with annual maintenance therapy consisting typically of just one treatment.

Conclusion: Radiofrequency with microneedling treatments for persistent LS showed significant improvement in LS symptoms. As LS is a chronic recurring condition, the treatment protocol resulted in high patient satisfaction for these women who had not experienced these results in terms of amount of symptom resolution or duration of symptom resolution with prior treatments using topical steroid cream or other modalities.

INTRODUCTION

Lichen sclerosus (LS) is a common chronic progressive mucocutaneous, immune-mediated inflammatory disease which typically involves genital skin causing it to become thin, friable, and hypopigmented. In some cases, the skin becomes more mottled with thin, white areas interspersed with areas of erythema and edema from chronic scratching secondary to itching. The lesions are typically flat, ivory, or porcelain white spots which may coalesce into pale, crinkly, thin patches and plaques. The disease occurs at all ages and in both sexes, but is more common in females than males.¹ LS most often affects the skin and mucosa of the vulva and perianal region, and is estimated to occur in 1 in 70 women.² However, LS is often overlooked, underdiagnosed, or misdiagnosed, so the actual incidence is likely even higher. Regardless of its exact incidence, vulvar LS is one of the most common referrals for vulvar distress and/or structural changes.^{1,3}

The entire vulva may be involved with possible extension to perineum and perianus, giving rise to the characteristic “figure of eight shape.”¹ Symptoms are marked by intense itching, pain, and skin tearing. These symptoms are usually cyclical and occur in flares; however, lichen sclerosus can range from being asymptomatic to always present.⁴ The exact etiology and pathogenesis of lichen sclerosus are not fully understood. There is a genetic and familial predisposition in LS, and frequent trauma, hormonal status, and certain drugs can also play a role.⁵ There is a well-known historically bimodal presentation of vulvar LS with a first peak in pre-pubertal girls (average: 7.6 years) and a second one during peri- and postmenopause (average: 52.6 years), which is linked to a low estrogen

status.^{5,6} LS is typically diagnosed clinically by the combination of the classic appearance of the skin on the vulva and the patient’s symptoms; however, biopsy can be used to confirm the diagnosis and rule out other causes such as malignancy or vulvar intraepithelial neoplasia. Four to six percent of women with LS will develop vulvar carcinoma.²

Traditionally, the treatment for symptomatic lichen sclerosus is the application of clobetasol propionate, a high-dose topical steroid cream or ointment, applied once or twice daily for up to three months or until symptom resolution.⁴ After initial treatment, the patient will most often have to continue the use of the topical steroids on an as-needed basis whenever the condition flares again. For some women, this is a never-ending cycle that seems to be more present than not. In many patients, the symptoms of LS are not controlled or they become refractory to corticosteroid therapy. LS can have a huge effect on a woman’s quality of life (QOL) as the chronic itching can be unrelenting and usually worsens at night which disturbs sleep. LS can cause skin breakdown from chronic excoriations, forming non-healing grooves in the skin. LS can also cause the clitoris and labia to become scarred and fused, the hood can become buried and flattened, unable to be differentiated from the labia. The vaginal introitus may also become narrowed from scarring. All of this affects intimacy as the thinned skin tears, causing fissures on the clitoral hood, labia, and perineum during intercourse. This leads to pain, bleeding, and scarring all resulting in sexual dysfunction.⁷

Prior studies have looked at alternative therapies to topical steroid treatment including: other topical agents such as calcineurin inhibitors and topical retinoids, platelet rich plasma (PRP), phototherapy, high-intensity focused

ultrasound (HIFU), and fractional CO₂ laser (FxCO₂), all with various levels of improvement, but none have stood out as an ideal second-line treatment for vulvar LS that is recurrent or refractory to corticosteroids.^{1,8,9}

MATERIALS AND METHODS

We conducted a retrospective study at a single site. All procedures were performed by one of two board-certified gynecologists.

Thirty-three female patients between the ages of 40 and 80 with symptoms and diagnosis of lichen sclerosus that were non-resolving with the traditional treatment of clobetasol propionate were treated with FormaV™ and Morpheus8V™ on the EmpowerRF™ platform (InMode Aesthetics, Lake Forest, California). The patients were from a single gynecology practice. The diagnosis of lichen sclerosus was made by either vulvar biopsy or clinical presentation and symptoms. The patients had made the decision to opt for further treatments due to the non-resolution of their LS symptoms. Any treatments, such as estrogen cream or clobetasol ointment were discontinued prior to treatment and for the duration of the study. The study treatment used was the combination of the EmpowerRF™ modalities: FormaV™ and Morpheus8V™ (Fig. 1a and b). FormaV™ is a bipolar radiofrequency device that provides dermal and subdermal heating. RF has been shown to produce new collagen, elastin, and blood vessel formation as skin surface temperatures reach 40–45°C.¹⁰ Morpheus8V™ is a microneedling fractional device with programmable penetration depth and energy delivery. The coated needles penetrate into the sub-dermal tissue (adjustable to 1, 2, and 3mm depths), coagulating fat and contracting connective tissue. Simultaneously, directional RF

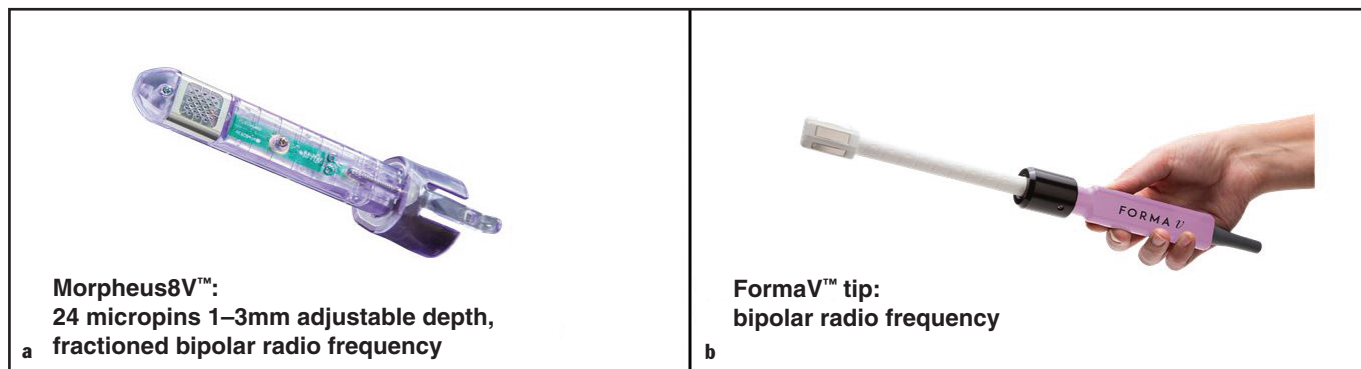


Figure 1a. Morpheus8V™ tip: 24 micropins 1–3mm adjustable depth bipolar radiofrequency. b) FormaV™ handpiece bipolar radiofrequency.

energy generates bulk sub-necrotic heat in the dermis. This directional RF energy stimulates neocollagenesis, elastogenesis, and angiogenesis.¹⁰ Questionnaires were given to the women pre- and post treatments to evaluate the improvement in lichen sclerosus symptoms, including tearing and thinning of the vulvar and perianal skin, itching, pain, dyspareunia, vaginal infection frequency, urinary tract infection (UTI) frequency, and decreased sensation. Health intake summaries were performed and patients were excluded if they had the presence of a pacemaker, internal defibrillator, or other active electrical implant in the body. Patients were also excluded from treatment if they were pregnant or had a current vulvar or perianal cancer.

The patients underwent a series of treatments, with the initial protocol con-

sisting of three treatments spaced four to eight weeks apart. Maintenance treatments were then performed annually or at the return of symptoms.

The patients were pretreated with Lidocaine 23% – Tetracaine 7% for 20 minutes prior to the start of the procedure. The treatment protocol was then started with a 10-minute application of the FormaV™ bipolar RF handpiece to the vaginal canal, introitus, labia majora, labia minora, clitoris, perineum, and peri-anal region. The FormaV™ handpiece was applied over all the regions of the vulva and vagina affected by lichen sclerosus, adequately heating the tissue to the optimal temperature of 42 to 43°C. The power setting was set at 35 watts. Directly after the FormaV™ treatment was completed, the Morpheus8V™ treatment was initiated. The Morpheus8V™

device was used in a stamping method to cover the entire length of the vagina internally in a 360° fashion with a 50% overlap. Two passes of single pulses were used at a depth of 3mm, 2mm, and 1mm, respectively.

Following internal vaginal treatment, the Morpheus 8V™ was then used externally in the same stamping method of 50% overlap to cover the entire vulvar and peri-anal area, again with two passes at each depth with a 50% overlap ensuring treatment of all areas affected by LS.

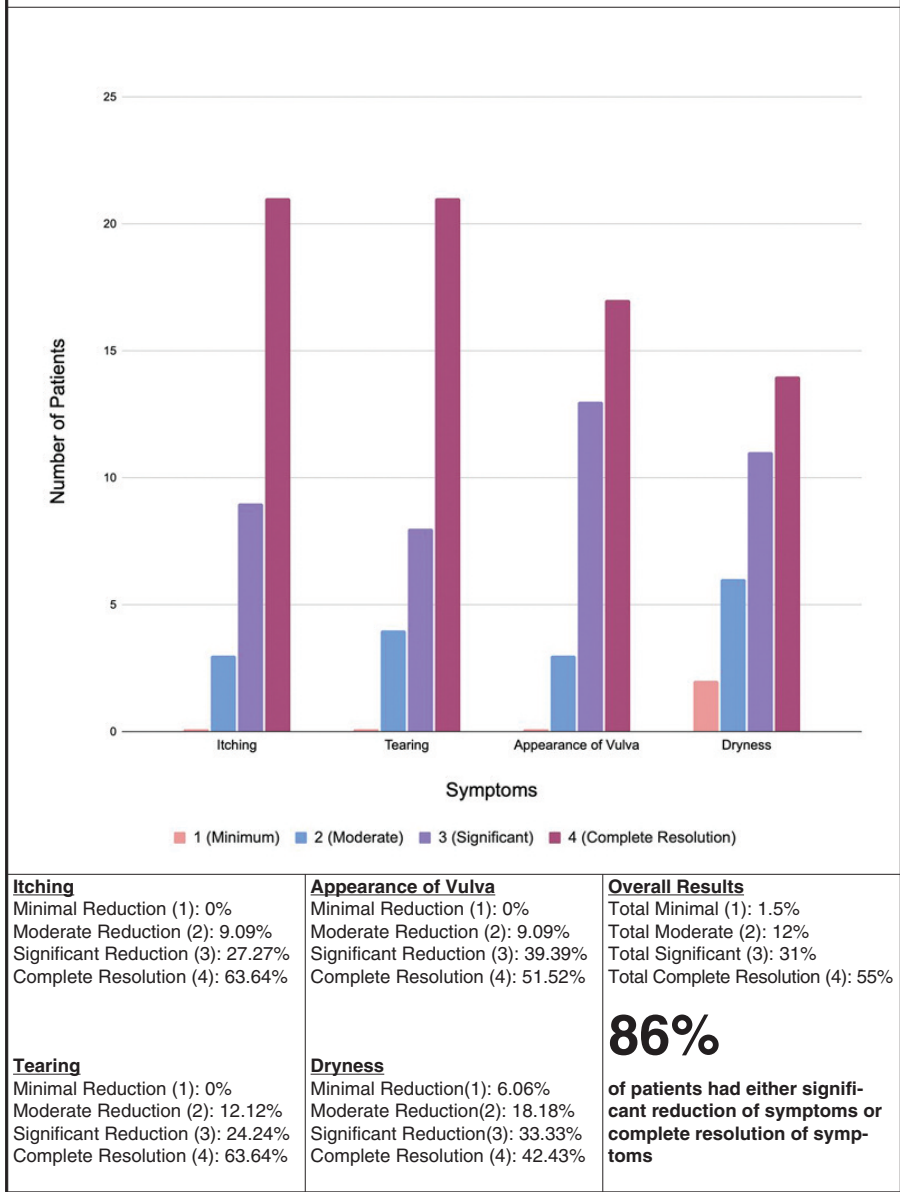
RESULTS

Data was collected from the patient questionnaires, pre- and post-procedure physical examinations and follow-up examinations (Figs. 2a–d). This data was

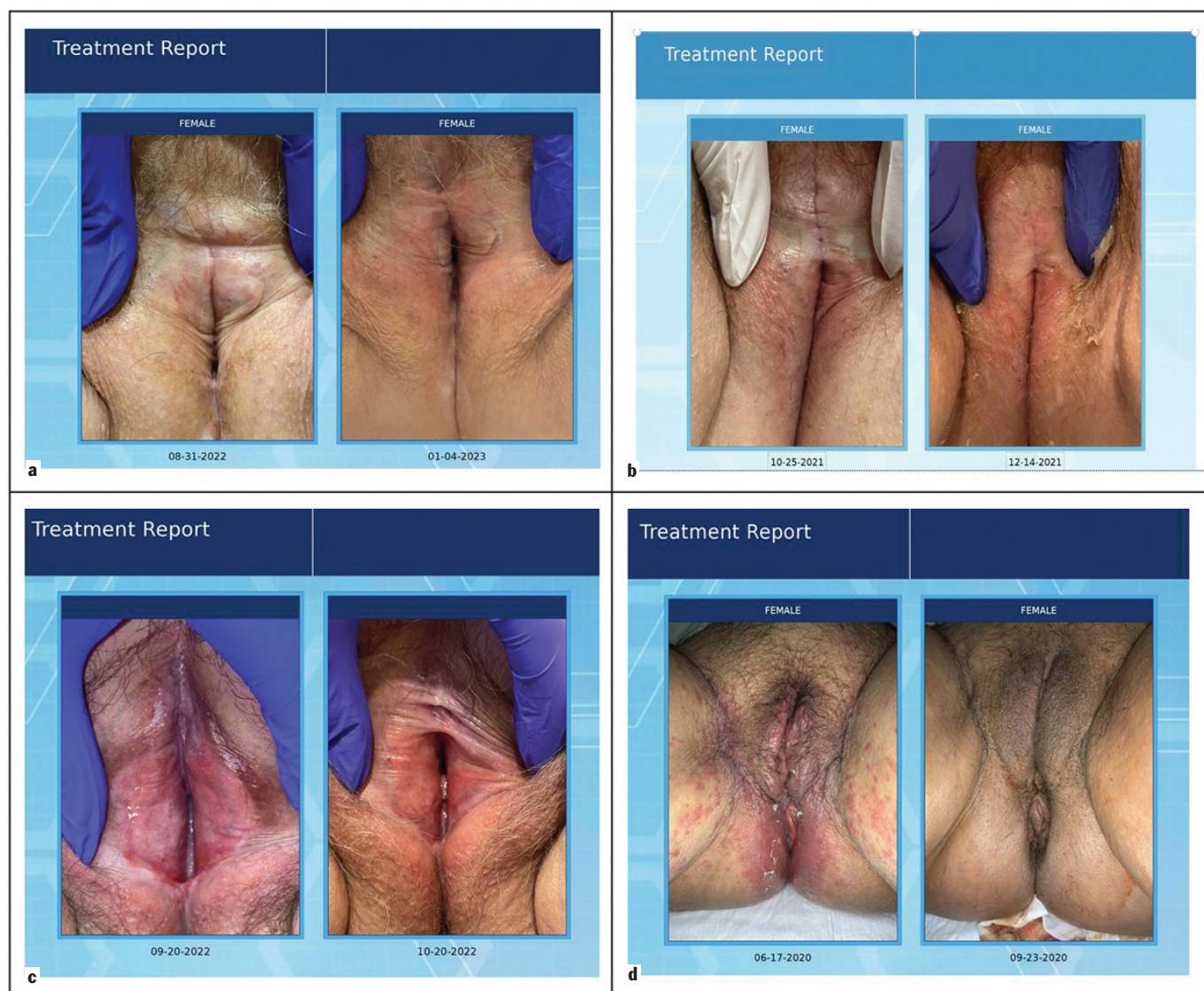

Figure 2a. Before treatment and six months post treatment. **b)** Before treatment and two months post treatment. **c)** Before treatment and one month post treatment. **d)** Before treatment and three months post treatment.

Table I
Lichen sclerosus symptoms



lack of improvement of symptoms with traditional treatments such as estrogen or clobetasol cream. Multiple facets of the disease must be managed by the patient including symptoms, concerns of developing vulvar carcinoma, sexual dysfunction, and the associated psycho-social aspects of the disease. While standard treatment of topical corticosteroids is successful in many VLS cases, especially in those diagnosed early, there is a large subset of patients with persistent symptoms of the disease.^{11,12}

Studies in the past have shown some success utilizing a CO2 laser to treat vulvar LS. Early studies showed some success; however, there were treatment complications and prolonged healing of several weeks.¹¹ More recent studies have shown positive outcomes in achieving remission with fractional CO2 lasers; however, maintenance was required with continued treatment of topical steroids.¹⁰ Postoperative pain was a common report in most studies.¹ Some authors thus have concluded that CO2 lasers are not effective enough as monotherapy for vulvar LS and it should only be performed as adjuvant therapy in addition to topical steroids.⁵

Microablative fractional radiofrequency (MFR) was studied as a therapeutic option for vulvar LS. The depth of the needles are only 0.8mm and do not penetrate the skin, but they do produce microablation at 1mm intervals. The needles gently touch the tissue, without penetrating it, to transmit electromagnetic current. Twenty-six patients were studied in this pilot study with 40% of patients reporting complete remission of symptoms. After two to three treatment sessions of MFR, most participants reported an improvement of symptoms for about 11 months (range: 7–16 months) after the treatment. At histologic evaluation, type III collagen concentration significantly increased and was associated with symptom improvement. MFR has also been shown to be effective in treating genitourinary symptoms of menopause and vaginal atrophy in several studies.¹³

The current study was the first study to evaluate the use of a combination of bipolar RF (FormaV™) and RF with true microneedling at a treatment depths of 1, 2, and 3mm (Morpheus8V™) in the treatment of persistent vulvar LS. Morpheus8V™ delivers fractional radiofrequency energy through bipolar arrays of micropin electrodes providing intravaginal and vulvar submucosal remodeling.

used to calculate percentages (Tables I and II). Patients’ responses about the reduction or resolution of LS symptoms for the vulvar, perianal region, and the vaginal canal were recorded and graphed. The most common symptoms of itching, tearing of tissue, changes in the appearance and color of tissue, and dryness of skin and tissue were recorded and compared. Scores of 1 through 4 were used to measure the response of the LS symptoms to the FormaV™ Morpheus8V™ treatment: a score of 1 representing minimal reduction of symptoms (25% improvement), a score of 2 for moderate reduction of symptoms (50% improvement), a score of 3 for significant resolu-

tion of symptoms (75% improvement), and a score of 4 for complete resolution of the symptoms.

The length of time between resolution of symptoms and the recurrence of the symptoms was also recorded and grouped in three-month increments with three to six months being the least amount of time for the duration of symptom resolution and over 12 months being the longest.

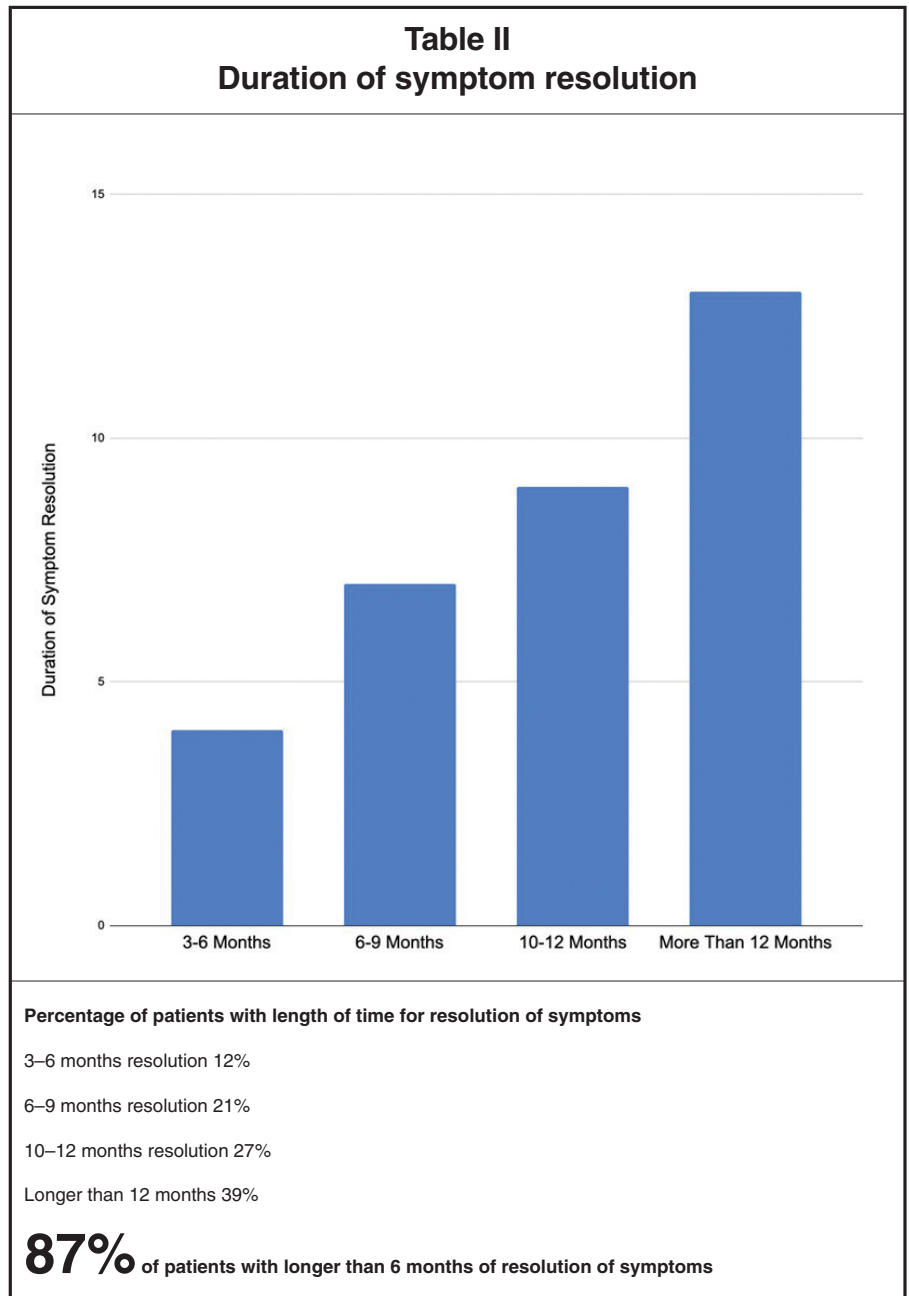
DISCUSSION

Management of vulvar LS can be very difficult and challenging. Most women get very frustrated with recurrences or

The handpiece has 24 gold-coated micropins, each pin is 300 micrometers in diameter with an insulated 0.5mm conductive tip with adjustable treatment depth. In contrast to lasers and microablative RF, where the thermal effect is limited by the ablation crater, the RF energy flows through the whole dermis, adding volumetric heating to fractional treatment. This ultimately delivers the energy deeper into the tissues, resulting in improved treatment zones.¹³ Most microneedling devices that utilize RF have delivered the energy between the needle tips alone; however, in the InMode Morpheus8™ line, the RF energy is applied between the needle and the external electrode applied to the skin surface. Each needle has a strong thermal effect, resulting in a larger and deeper treatment zone.

Results demonstrated a significant improvement of LS symptoms with the use of a combination therapy utilizing bipolar RF (FormaV™) and RF with microneedling (Morpheus8V™) therapy, with 55% of patients having complete resolution of their vulvar LS symptoms. The patients received three treatment sessions, four to eight weeks apart, that were well-tolerated. The data from the questionnaires showed a significant reduction or complete resolution in the symptoms of itching, tearing, and dryness of the tissue, with 86% of the patients reporting either significant or complete resolution of the most common LS symptoms. In the case of itching, which is typically one of the most severe symptoms of LS, 91% of patients reported significant or complete resolution. This resulted in a high patient satisfaction for the treatment.

Visual inspection of the appearance of the tissue by the treating physicians also showed significant improvement with the return of color in the hypopigmented areas and the resolution of erythema and excoriations. 87% of patients reported significantly less tearing of tissue or the complete resolution of tearing, and 90% of patients reported significant or complete improvement in the overall appearance of the vulvar tissue. The resolution of clitoral adhesions and chronic inflammation can improve the patient's perception of her genitals and self-esteem. Also, improving the scarring and tears decreases dyspareunia, resulting in improved sexual function and intimacy. In a study of the histologic effects of a monopolar RF



device alone on the vulvar and vaginal tissues showed 80% of the vulvar samples and 100% of the vaginal samples demonstrated thickened mucosa and neovascularization. Neocollagenesis was noted on all post-treatment vulvar and vaginal samples,¹⁴ which ultimately leads to healthier, stronger tissue.

Dryness of the tissue also improved in the current study, with 75% of patients reporting significant reduction or complete resolution of this symptom. Though this percentage improvement is less than the improvement in the other common symptoms, it is still markedly improved from the traditional treatments for LS. Previously, non-ablative

RF therapy has been shown to be effective in treating genitourinary symptoms of menopause (GSM), including dryness.¹⁴

The duration of resolution of the LS symptoms in the current study lasted at least six months, with the majority of the patients having results that lasted over 12 months. 87% of patients reported relief of symptoms lasting six months or more before recurrence. Historically, these patients just require one booster treatment of FormaV™ Morpheus8V™ to resolve any recurrent symptoms they may have.

One limitation of our study was that it is retrospective and limited by size.

However, a strength was that our sample showed a wide range of women affected by lichen sclerosus with the ages ranging from 40 to 80 years old, the average age being 69.3 years.

Another limitation of our study was that the patients were not separated by the initial severity of the LS symptoms. However, all of the patients were in the moderate-to-severe range for symptoms since they had already failed traditional LS treatment. Thirty out of 33 patients were already using Estradiol cream and Clobetasol cream without significant response, leading to them seeking out further treatments.

The last limitation of our study was that post-treatment care was not standardized, with a variety of topical post-procedure creams for healing used in different patients (non-medical). In a prospective study, a standardized post-procedure treatment protocol could be utilized. Additionally, regenerative therapies, such as PRP, may have a role in adjuvant therapy with Morpheus8V™ in the future. Early studies have shown PRP to improve QOL and objective parameters in vulvar LS.^{5,15}

CONCLUSION

This is the first study to report on the use of bipolar RF and RF with microneedling for the treatment of lichen sclerosus occurring on the vulva and vaginal canal. Preliminary data indicates that EmpowerRF™ treatment combination with FormaV™ and Morpheus8V™ resulted in significant improvement in the most common symptoms of lichen sclerosus in patients that were not being controlled with traditional treatment of topical steroid cream. In our clinical

population, we observed improvement in LS symptoms compared to other treatments that we had been using in the past such as PRP, HIFU, and FxCO2.

In our clinical practice, we have seen overwhelmingly positive results using radiofrequency with microneedling for treatment of chronic lichen sclerosus that has been resistant to or suboptimally treated with topical steroid cream. Our retrospective collection of data shows the combination of FormaV™ and Morpheus8V™ treatments for LS had a high patient satisfaction and improvement in quality of life. Our patients experienced better symptom resolution and longer duration of symptom resolution with radiofrequency treatment over topical steroid cream that they had used in the past. The majority of our patients wanted to continue receiving treatments due to the benefits they gained and opted to receive annual maintenance treatment or treatment on first signs of recurrence. FormaV™ and Morpheus8V™ treatment for LS shows promise to become a significant option for the many women who suffer daily with lichen sclerosus. We feel that with a prospective study and a larger sample size we can show clinically significant results of treatment of lichen sclerosus with FormaV™ and Morpheus8V™. **STI**

AUTHORS' DISCLOSURES

Dr. Blusewicz is a stockholder, speaker, and consultant for InMode Aesthetics, California. Dr. Miklos and Dr. Moore are stockholders, consultants, speakers, and receive research grants from InMode Aesthetics, California. Dr. Coley has no conflicts of interest to disclose.

REFERENCES

1. Corraza MC, Schettini N, Zedde P, et al. Vulvar lichen sclerosus from pathophysiology to therapeutic approaches: evidence and prospects. *Biomedicines* 2021;9:950.
2. Bleeker MC, Visser PJ, Overbeek LI, et al. Lichen sclerosus: incidence and risk of vulvar squamous cell carcinoma. *Cancer Epidemiol Biomarkers Prev* 2016;25: 1224–30.
3. Goldstein AT, Marinoff SC, Christopher K, et al. Prevalence of vulvar lichen sclerosus in a general gynecology practice. *J Reprod Med* 2005;50: 477–80.
4. Amal Chamli; Asmahane Souissi, NIH National Library of Medicine. Lichen Sclerosus - Stat Pearls. [Internet]
5. De Luca DA, Papara C, Vorobyev A, et al. Lichen sclerosus: The 2023 update. *Front Med* 2023;10: 1106318.
6. Kirtschig G, Becker K, Gunthert A, et al. Evidence-based (s3) guideline on (anogenital) lichen sclerosus. *J Eur Acad Dermatol Venereol* 2015; 29:e1–43.
7. Preti M, Scurry J, Micheletti L, et al. Vulvar intraepithelial neoplasia. *Best Pract Res Clin Obstet Gynaecol* 2014;28(7):1051–62.
8. Krapf JM, Mitchell L, Holton MA, et al. Vulvar lichen sclerosus: current perspectives. *Int J Womens Health* 2020;12:11–20.
9. Mitchell L, Goldstein AT, Heller D, et al. Fractionated carbon dioxide laser for the treatment of vulvar lichen sclerosus: a randomized controlled trial. *Obstet Gynecol* 2021;137(6):979–87.
10. Dayan E, Burns AJ, Rohrich RJ, et al. The Use of Radiofrequency in Aesthetic Surgery. *Plast Reconstr Surg Global Open*. 2020Aug;8(8):e2861.
11. Stewart K, Javaid S, Schallen K, et al. Fractional CO2 laser treatment as adjunctive therapy to topical steroids for managing vulvar lichen sclerosus. *Lasers Surg Med* 2022;54:138–51.
12. Lee A, Bradford J, Fischer G. Long-term management of adult lichen sclerosus: a prospective cohort study of 507 women. *JAMA Dermatol* 2015;151(10): 1061–7.
13. Kamilos MR, Aguiar LM, Batista VH, et al. Microablative fractional radiofrequency as a therapeutic option for vulvar lichen sclerosus: a pilot study. *Clinics (Sao Paulo)* 2021.PMID:33787656
14. Stachowitz AM, Hoover ML, Karram MM. Clinical utility of radiofrequency for female genitourinary dysfunction: past, present, and future. *International Urogyn J* 2021;32:1345-1350.
15. Eshtiaghi P, Sadownik L, Fact or fiction? Adipose-derived stem cells and platelet-rich plasma for the treatment of vulvar lichen sclerosus. *J Low Genit Tract* 2019;23:65–70.



Copyright © 2023
Surgical Technology International™
Tel. 1 415 436 9790
Email: info@surgicaltechnology.com
Internet: www.surgicaltechnology.com
Surg Technol Int. 2023, Nov 20; 43. pii: sti43/1743