The Current Role of the Percutaneous Arteriovenous Fistula for Hemodialysis Access

Krystina N. Choinski, MD[1]
Vascular Surgery Resident

Scott A. Sundick, MD, FACS[2]
Board-Certified Vascular Surgeon and General Surgeon

Ajit G. Rao, MD[1]
Director of Vascular Surgery Research
Assistant Professor of Surgery and Radiology

Windsor Ting, MD[1]
Associate Professor of Surgery

Peter L. Faries MD, FACS[1]
System Chief of Vascular Surgery of Mount Sinai Health System
Program Director of Vascular Surgery
Professor of Surgery and Radiology

Rami O. Tadros MD, FACS, RPVI[1]
Site Director of Endovascular Aortic Surgery at Mount Sinai East
Senior Associate Program Director of Vascular Surgery
Associate Professor of Surgery and Radiology

[1]Division of Vascular Surgery, Department of Surgery, Mount Sinai Hospital, Icahn School of Medicine at Mount Sinai, New York, New York
[2]Department of Vascular Surgery, Overlook Medical Center, The Cardiovascular Care Group Westfield, New Jersey

ABSTRACT

Dialysis is the preferred treatment for patients with end-stage renal disease (ESRD) for the removal of accumulated toxins secondary to compromised renal function. Hemodialysis has traditionally been performed via a surgically created arteriovenous fistula (AVF) or arteriovenous graft (AVG). Novel endovascular techniques have allowed for the creation of percutaneous arteriovenous fistulas for hemodialysis access. Two devices, the Ellipsys® Vascular Access System (Avenu Medical, Inc., San Juan Capistrano, California) and the WavelinQ™ EndoAVF System (C.R. Bard, Inc., Murray Hill, New Jersey), are currently available for percutaneous AVF creation and investigation of their utility is ongoing. This paper describes the current utilization, differences, and results thus far with these devices and, additionally, investigates the contemporary advantages, disadvantages, and selection criteria for percutaneous AVFs overall.

INTRODUCTION

Hemodialysis has been utilized in the removal of accumulated toxins, electrolytes, and excess fluid in chronic renal failure patients[1] since the 1960s.[2] By developing veno-venous access[3] and, ultimately, the surgical arteriovenous fistula (AVF),[4] Brescia and Cimino improved dialysis access from the previous use of Teflon shunts.[2,5,6] Since then, fistulas have been the ideal access for hemodialysis, with superior patency once mature, less secondary interventions, and lower complication rates, including infection and dialysis access steal syndrome (DASS) in comparison to grafts.[7,8] Both AVFs and arteriovenous grafts (AVGs) are preferred over tunneled catheters, which are associated with increased mortality risk and higher rates of infection.[9-12]

Surgical access remains first line for hemodialysis, but novel devices now offer the option of a percutaneous AVF (pAVF) as an alternative.[13-15] These minimally invasive procedures were developed in an attempt to address the current underutilization of AVFs, where only 14% of patients in the United States initiate hemodialysis via AVF in contrast to 83% via catheter.[12] This could be secondary to surgical wait times,[16] lack of clinical maturation,[17] and procedures required to facilitate the maturation or maintenance of surgical AVFs.[18,19] Here we investigate the clinical outcomes thus far with percutaneous AVFs and explore the role the procedure has in hemodialysis access today.

DEVICES FOR PERCUTANEOUS ARTERIOVENOUS FISTULA CREATION

Both pAVF devices are centered around the vascular anatomy of the proximal forearm in the creation of the fistula. Essential to the success of the pAVF is the deep communicating vein, which

Table I
Comparison of the two percutaneous arteriovenous fistula devices

	WavelinQ™ EndoAVF System	Ellipsys® Vascular Access System
Device Components	Two 4Fr, magnetic, hydrophilic coated catheters (venous catheter with radiofrequency electrode and arterial catheter with backstop for receiving the electrode), ESU-1 electrosurgical unit, and electrosurgical pencil	Access needle, 6Fr over-the-wire tissue fusion and cutting catheter, and a power controller
Mechanism of Fistula Creation	Radiofrequency energy	Thermal resistance energy and pressure
Access Sites	Arterial and venous: brachial artery/vein, ulnar artery/vein, or radial artery/vein	Venous: cephalic, median cubital, median basilic, or brachial vein
Site of Fistula Creation	Proximal ulnar artery and ulnar vein or proximal radial artery and radial vein	Proximal radial artery and deep communicating vein
Contrast Required?	Yes, fluoroscopic imaging used to confirm catheter alignment and for confirmation fistulogram	No, ultrasound guidance only
Additional Procedures at Time of Fistula Creation	Brachial vein coil embolization or AMPLATZER™ plug (Abbott Laboratories, Chicago, Illinois)	Immediate balloon angioplasty of the anastomosis with a 5 x 20mm balloon

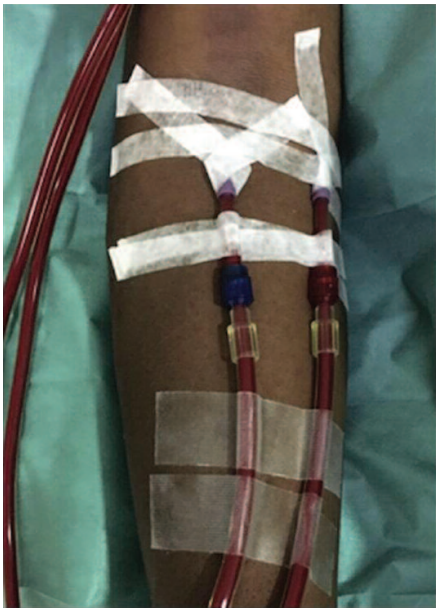

Figure 1. Patient with Y-shaped pAVF undergoing two-needle cannulation for dialysis.

Figure 2. WavelinQ™ EndoAVF System: venous catheter with radiofrequency electrode, arterial catheter, ESU-1 electrosurgical unit, and electrosurgical pencil.

allows for diversion of arterialized blood flow from the deep to superficial venous system once an arteriovenous connection has been established.[20-22] This connection is a side-to-side anastomosis between either the proximal ulnar artery to ulnar vein[14,23] or the proximal radial artery directly to the deep communicating vein,[15,22,24] depending on the choice of device (Table I). Pre-procedural arterial and venous mapping are essential to establish the arterial diameter, venous diameter, and proximity of the two vessels prior to pAVF creation. Once formed, these endovascular anastomoses are similar to surgical anastomoses previously described by Toledo[25] and Gracz.[26] Maturation of the superficial veins following pAVF creation ultimately allow for cannulation of either the cephalic, median cubital, basilic, or combination of two veins[20-22] which form a unique, Y-shaped fistula for hemodialysis (Fig. 1).[27]

WavelinQ™ EndoAVF System

The WavelinQ™ EndoAVF System (C.R. Bard, Inc., Murray Hill, New Jersey) (Fig. 2) is a dual catheter-based system that creates an anastomosis typically between the proximal ulnar artery and ulnar vein.[14,20,21,23] With the original 6 Fr system, ultrasound-guided access through the brachial vein and brachial artery is achieved, followed by guidewire placement into the ulnar vein and artery. This is followed by the advancement of both catheters to the desired location with position confirmation by fluoroscopy. The two catheters are aligned via magnets, holding the artery and vein together and aligning the radiofrequency

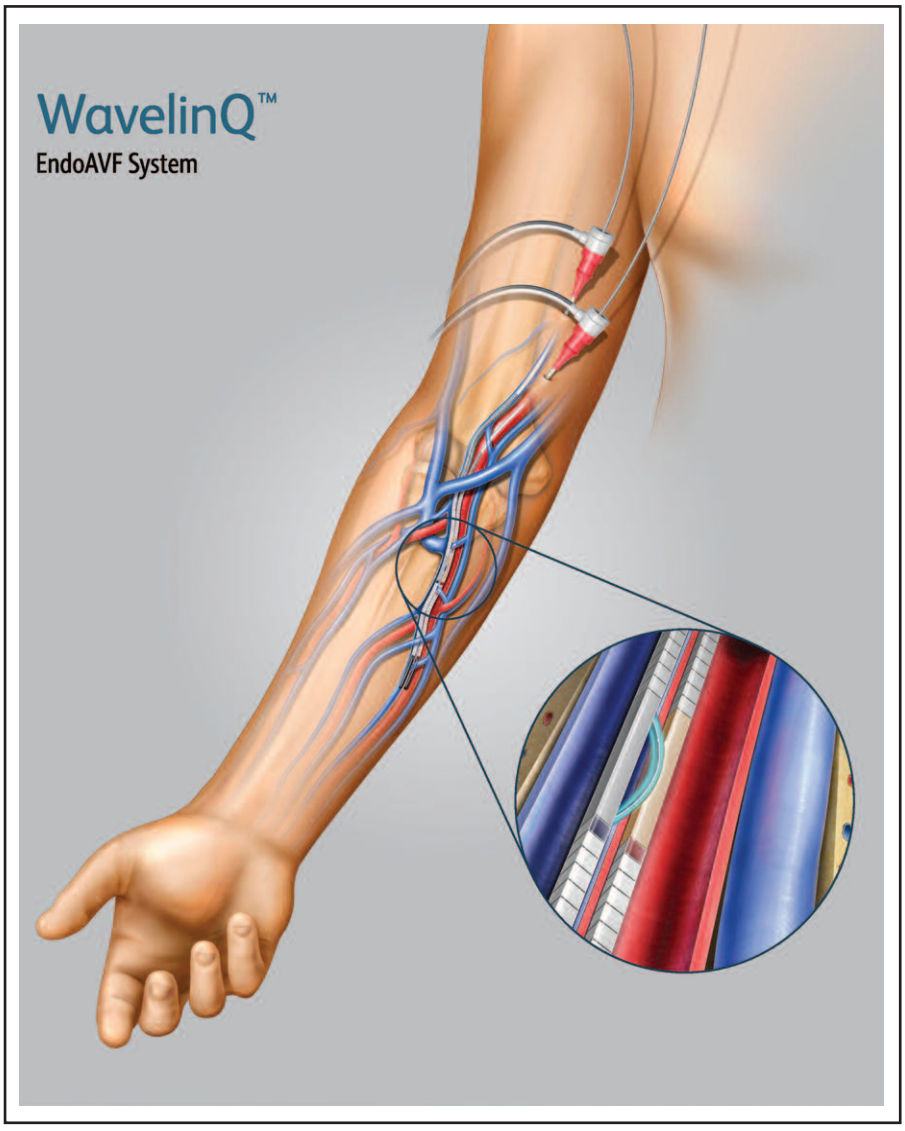

Figure 3. Illustration of venous and arterial catheters aligned via magnets in the proximal ulnar vein and artery. The radiofrequency electrode in the venous catheter is deployed toward the ceramic backstop of the arterial catheter to create a percutaneous arteriovenous fistula.

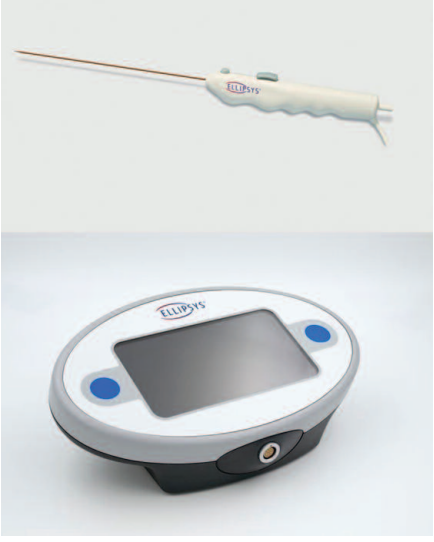

Figure 4. Ellipsys® Vascular Access System: Ellipsys® catheter and power controller.

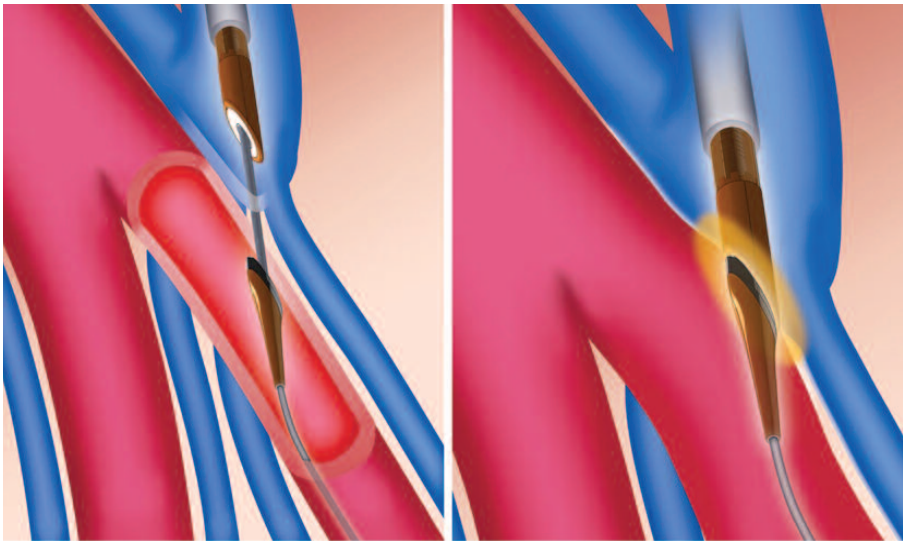

Figure 5. Illustration of Ellipsys® catheter with distal tip in "open" position in the proximal radial artery and then with the device closed, capturing the radial artery and perforating/deep communicating vein.

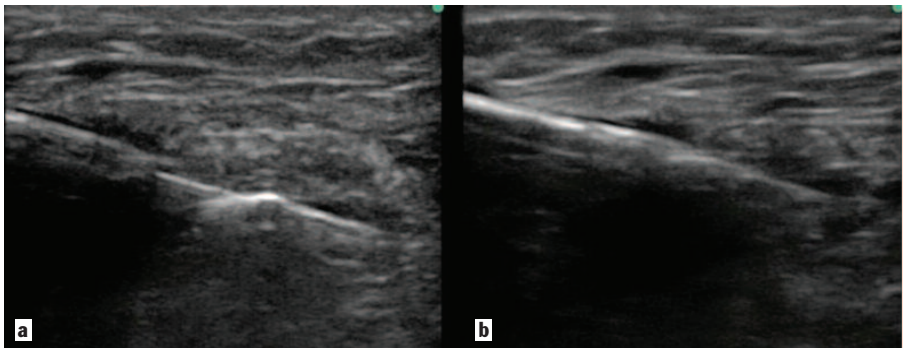

Figure 6a. Procedural ultrasound displaying advancement of the distal tip of the Ellipsys® catheter into the proximal radial artery. (b) Ellipsys® catheter with closure of device, capturing the radial artery and perforating the communicating vein.

(RF) electrode of the venous catheter with the ceramic backstop of the arterial catheter (Fig. 3). The RF electrode is then released, creating a side-to-side, approximately 5mm x 1mm, arteriovenous fistula between the ulnar artery and vein. Arteriogram is performed to confirm pAVF creation and the brachial vein is subsequently coil embolized to divert blood flow away from the deep venous system and toward the superficial veins.

A new, lower profile 4 Fr EndoAVF system has been developed allowing for alternative access sites at the radial and ulnar arteries/veins at the wrist in addition to the brachial artery/vein. There is also an additional option for pAVF creation between the radial artery and radial vein in addition to the proximal ulnar artery and ulnar vein.[21] This new system still features magnet alignment of both a venous catheter with RF electrode and arterial catheter with backstop. However, the catheters now have the ability to be aligned in either the same or opposite direction and the delivery of RF energy is brief, requiring 0.7 seconds to create the anastomosis, as opposed to two seconds with the original device. Coil embolization of the brachial vein is still performed prior to completion of the procedure.

Ellipsys® Vascular Access System

The Ellipsys® Vascular Access System (Avenu Medical, Inc., San Juan Capistrano, California) (Fig. 4) is a single-catheter, venous-access system that allows for the creation of a pAVF between the proximal radial artery and the deep communicating vein (DCV)/perforating vein.[15,22,24,28,29] This device uses thermal resistance energy and applied pressure to fuse the adventitia of the artery and vein and create an elliptical anastomosis between the two. The catheter features a 6 Fr proximal base and 5 Fr distal tip, which can be adjusted from the "open" to "closed" position (Fig. 5). During the procedure, ultrasound-guided access of the median basilic or median cephalic vein is achieved, followed by advancement of a wire and 6 Fr sheath. The 6 Fr sheath is positioned into the DCV where it is adjacent to the proximal radial artery. Constant ultrasound visualization is then utilized to advance a micropuncture needle and puncture the proximal radial artery. A wire is then advanced to confirm the connection between the proximal radial artery and DCV. Next, the sheath, followed by the Ellipsys® catheter in the "open" position, is advanced into the proximal radial artery. The sheath is retracted into the DCV and then traction is applied on the catheter, so the tip engages with the wall of the proximal radial artery. The catheter is then closed with verification of tissue capture on the power controller (Fig. 6). The device is activated to form an anastomosis, of about 4mm x 2mm, between the artery and vein, which is confirmed by duplex ultrasound (Fig. 7).

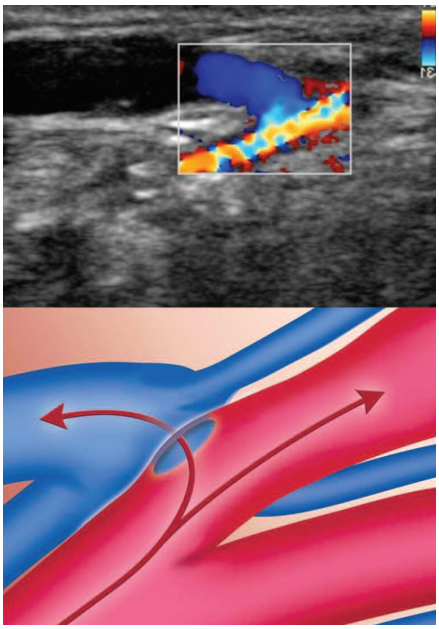

Figure 7. Ultrasound duplex and illustration displaying formation of an anastomosis between the proximal radial artery and the deep communicating vein.

Initial trials did not perform immediate percutaneous transluminal angioplasty at the time of creation of anastomosis.[15,24] However, immediate angioplasty of the anastomosis at time of creation allows for avoidance of balloon dilation as a secondary procedure soon after pAVF formation, improved flow through the fistula, and improved maturation.[22] Techniques for balloon dilation of the anastomosis at the time of creation and algorithms for maintenance and maturation of Ellipsys® pAVFs have been described.[29]

Patient selection

In all trials with pAVFs thus far, patients are only considered for the procedure if they are not candidates for a surgically created distal radiocephalic

Table II
Trials included in review and results analysis of percutaneous arteriovenous fistulas

WavelinQ™ EndoAVF System	Ellipsys® Vascular Access System	Meta-Analysis of Both Devices
Rajan (2015)* 33 patients Radosa (2017)* 8 patients Lok (2017)* 60 patients Berland (2019)* 32 patients	Hull (2017)* 26 patients Hull (2018)* 107 patients Mallios (2018)* 34 patients Beathard (2019) 105 patients Mallios (2020) 234 patients	Yan Wee (2019) 300 patients

**Included in the Meta-Analysis by Yan Wee et al*

AVF at the wrist. Patients were typically CKD IV/CKD V, planning for future dialysis, or already in end-stage renal disease (ESRD), receiving dialysis via a tunneled venous catheter. Patients with a previously failed surgical AVF were eligible for pAVF creation.

For the WavelinQ™ created pAVF, patients with target artery diameter >2mm, target vein diameter >2mm, and a distance of less than 2mm between the artery and vein were eligible for the procedure.[14,20,23] The presence of a deep communicating/perforating vein was confirmed via upper extremity duplex preoperatively and outflow of the cephalic and basilic vein was evaluated with preference of a diameter >2.5mm for the two. Ipsilateral central venous stenosis or upper extremity venous occlusion resulted in exclusion from creation of a WavelinQ™ pAVF.

For the Ellipsys® pAVF, patients were eligible for the procedure if arterial and venous duplex revealed a proximal radial artery diameter >2mm and deep communicating vein/perforating vein >2mm. Additionally, a distance of <1.5mm between the two vessels was required for proper anastomosis formation.[29] A positive Allen test, or upper extremity arterial stenosis (>20mm/Hg systolic BP difference between arms), could exclude a patient from being eligible for an Ellipsys® pAVF.[24]

Results with percutaneous arteriovenous fistulas

Multiple trials have investigated both devices and outcomes with the pAVF creation, including a metanalysis of the two (Table II). Both the WavelinQ™ and Ellipsys® devices had a high technical success rate in pAVF creation (Table III), ranging from 94–100% for the WavelinQ™ and 88–100% for the Ellipsys®. Pooled meta-analysis displayed a technical success rate of 97.5% for pAVF creation.[13] A combination of vascular surgeons, an interventional radiologist, and an interventional nephrologist performed these pAVF procedures. Clinical maturation of the pAVF was defined as a brachial artery flow >500mL/min and access vein diameter >4mm, which was achieved by an average of 89% of overall pAVFs created in studies thus far (Table III).

Looking at the patency of pAVFs, current trials have various analyses of this variable in terms of length of study and primary versus secondary versus

Table III
Analysis of successful creation, maturation, and patencies of percutaneous arteriovenous fistulas

					3 Months			6 Months		1 Year		
		Successful Creation (%)	Maturation (%)	Mean Time to Maturation[a] (Days)	Primary Patency (%)	Primary Assisted Patency (%)	Secondary Patency (%)	Cumulative Patency (%)	Primary Patency (%)	Cumulative Patency (%)	Primary Patency (%)	Primary Assisted Patency (%)	Secondary Patency (%)	Cumulative Patency (%)
WavelinQ™	Rajan (2015)*	97 (32/33)	96 (27/28)	58 (37-168)	-	-	-	-	-	96.2	-	-	-	-
	Radosa (2017)*	100 (8/8)	100 (7/7)	63 (26-137)	-	-	-	-	-	100	-	-	-	-
	Lok (2017)*	98 (59/60)	87 (52/60)	-	-	-	-	-	-	-	69	-	-	84
	Berland (2019)*	94 (30/32)	91 (29/32)	-	83	-	-	87	83	87	-	-	-	-
	Yan Wee (2019):	99.45	88.17	-	-	-	-	-	-	92.61	-	-	-	-
Ellipsys	Hull (2017)*	88 (23/26)	77 (20/26)	-	-	-	-	-	-	88	-	-	-	75
	Hull (2018)*	95 (102/107)	86 (92/107)	62.4 (34-345)	-	-	-	91.6	-	89.3	-	-	-	86.7
	Mallios (2018)*	97 (33/34)	97 (33/34)	-	82	94	94	92	-	-	-	-	-	-
	Beathard (2019)	100 (105/105)	98 (103/105)	-	-	-	-	-	-	97.1	-	-	-	93.9
	Mallios (2020)	99 (232/234)	-	28 (7-84)	-	-	-	-	-	-	54	85	96	96
	Yan Wee (2019):	95.19	89.35	-	-	-	-	-	-	90.98	-	-	-	-
Overall	Yan Wee (2019)	97.5	89.27	89.27	-	-	-	-	-	91.99	-	-	-	85.71

* Included in Yan Wee Meta-Analysis
[a]Definition of Clinical Maturation: Brachial artery flow > 500 mL/min, Vein diameter > 4 mm

Table IV
. Percentage of successful cannulation and functional usability of percutaneous arteriovenous fistulas for hemodialysis

		% Successful Cannulation	Mean-time to Cannulation	Functional Usability*	Average Days on HD
WavelinQ™	Rajan (2015)	25/27 (93%)	-	25/27 (93%) at 6 months	-
	Radosa (2017)	7/7 (100%)	-	-	-
	Lok (2017)	28/44 (64%)	111.8 days (baseline HD) & 32.4 days (pre-HD)	28/44 (64%) at 2 months	-
	Berland (2019)	21/27 (78%)	43 days +/-14	20/27 (74%) at 3 months	-
Ellipsys	Hull (2017)	16/20 (80%)	108 days +/- 61	-	354 days +/- 177
	Hull (2018)	71/81 (88%)	100.3 days +/- 51.9 (baseline HD) & 162.9 days +/- 86.6 (pre-HD)	-	114.3 days +/- 66.2
	Mallios (2018)	24/34 (71%)	-	-	-
	Beathard (2019)	100/105 (95%)	-	-	-
	Mallios (2020)	-	-	-	-

*Functional Usability: Use of fistula for > 2/3 of HD sessions

Table V
Procedure-related complications with percutaneous arteriovenous fistula formation

Procedure Related Complications	Rajan (2015)	Radosa (2017)	Lok (2017)	Berland (2019)	Hull (2017)	Hull (2018)	Mallios (2018)	Beathard (2019) Did not comment	Mallios (2020)
Pseudoaneurysm	2 (6%)	-	2 (3%)	-	-	-	-	-	-
Hematoma	2 (6%)	-	-	-	1 (4%)	-	-	-	-
Detached Tip of Venous Catheter	1 (3%)	-	-	-	-	-	-	-	-
Thrombosis of pAVF	1 (3%)	-	-	1 (3%)	3 (12%)	12 (11%)	-	-	-
Thrombosis of Brachial Artery	-	-	2 (3%)	-	-	-	-	-	-
Iatrogenic AVF between Brachial Artery/Vein	-	1 (13%)	-	-	-	-	-	-	-
Closure Device Embolization	-	-	2 (3%)	-	-	-	-	-	-
Brachial Artery Dissection	-	-	1 (2%)	-	-	-	-	-	-
Steal Syndrome	-	-	1 (2%)	-	-	1 (1%)	-	-	-
Venous Injury/Perforation	-	-	-	1 (3%)	-	1 (1%)	-	-	-
Tract Fistula	-	-	-	-	1 (4%)	-	-	-	-
Infection	-	-	-	-	-	1 (1%)	-	-	-
Total	6	1	8	2	5	15	0	-	0

cumulative patencies (Table III). Pooled meta-analysis data displays a cumulative patency for a WavelinQ™ pAVF of 92.6%, Ellipsys® pAVF of 90.9%, and overall cumulative patency of 91.9% at six months.[13] At the one-year mark, patencies have been more extensively studied for the Ellipsys® pAVF than the WavelinQ™ and appear to have a higher patency (Table III). Pooled patency at the one-year mark for overall pAVFs was 85.7%. Analysis for two year patency rate has only been conducted for the Ellipsys® pAVF [28], displaying a cumulative patency of 92.7%.

Percentage of successful two-needle cannulation for hemodialysis varied between trials (Table IV). Mean time to cannulation ranged from 32.4 to 169.2 days, with one study noting an average time of 32.4 days in a subset of patients who, at baseline, were non-hemodialysis dependent at the time of pAVF creation.[20] Of note, a smaller, single institution, retrospective cohort study has noted successful cannulation of pAVFs at less than 14 days post creation.[27] The dialysis protocol used for these patients was a dialysis blood flow rate of 300 to 350mL/min for four

Table VI
Secondary procedures utilized in the maturation and maintenance of percutaneous arteriovenous fistulas

Secondary Procedures	Rajan (2015)	Radosa (2017)	Lok (2017)	Berland (2019)	Hull (2017)	Hull (2018)	Mallios (2018)	Beathard (2019) Did not comment	Mallios (2020)
PsBalloon angioplasty	3 (9%)	-	2 (3%)	1 (3%)	20 (63%)	164 (>100%)	6 (18%)	-	96 (41%)
Thrombin injection	2 (6%)	-	2 (3%)	-	-	-	-	-	-
Superficialization (BVT, Lipectomy)	-	1 (13%)	5 (8%)	-	7 (30%)	28 (26%)	1 (3%)	-	24 (10%)
Basilic vein ligation	-	-	-	-	4 (17%)	-	-	-	-
Cubital vein ligation	-	-	-	-	-	17 (16%)	-	-	-
Coil embolization of tributary vein	-	-	5 (8%)	-	-	50 (46%)	-	-	-
Cubital vein embolization	-	-	-	-	-	17 (16%)	-	-	-
Brachial vein embolization	-	-	-	-	6 (26%)	42 (39%)	1 (3%)	-	-
Thrombolysis	-	-	1 (2%)	-	-	-	-	-	-
Thrombectomy	-	-	2 (3%)	1 (3%)	-	-	-	-	-
Stent graft	-	-	-	1 (3%)	-	8 (7%)	-	-	-
Valvulotomy	-	-	-	-	1 (4%)	-	-	-	-
pAVF Ligations	-	-	3 (5%)	-	-	-	-	-	-
pAVF Banding	-	-	-	-	-	-	-	-	1 (<1%)
Surgical artery repairs	-	-	2 (3%)	-	-	-	-	-	-
New surgical AVF/AVG	1 (3%)	-	2 (3%)	1 (3%)	-	-	1 (3%)	-	3 (1%)
Total Interventions	6	1	24	4	38	326	9	-	124
Interventions per patient-year	0.6	-	0.46	0.21	1.57	2.7	-	-	-

hours, three times a week.

Complications related to pAVF creation appear to be largely related to brachial artery access in early studies of the original 6 Fr WavelinQ™ EndoAVF system, including pseudoaneurysm, hematoma, iatrogenic AVF between the brachial artery and vein, thrombosis of the brachial artery, brachial artery dissection, and closure device complications (Table V). Wrist access with the use of the 4 Fr WavelinQ™ EndoAVF system appears to have decreased these complications.[21] Of note, recent studies with the Ellipsys® Vascular Access System have noted almost no complications during the procedure.[22,29] Pooled complication rates for creation of pAVF are 5.46% overall, at 8.59% for the WavelinQ™ and 2.48% for Ellipsys®.

Both endovascular and open secondary interventions were required for the maturation and maintenance of pAVFs (Table VI). Balloon angioplasty was most frequently used for the Ellipsys® pAVF rather than the WavelinQ™ pAVF. For redirection of flow to the desired vein for cannulation, multiple methods were implemented including coil embolization of cubital/brachial/accessory veins, basilic vein ligation, and cubital vein ligation. Additionally, surgical superficialization in the form of basilic vein transposition (BVT), or lipectomy, was required for cannulation in multiple studies for both the WavelinQ™ and Ellipsys® pAVF, ranging from 3–30% of patients in the studies. Conversion to surgical AVF or AVG was required for 1–3% of patients.

Advantages of percutaneous arteriovenous fistulas

One advantage offered by a pAVF versus a surgical AVF in the proximal forearm is the lower flow through a pAVF in comparison to a brachial artery fistula.[24] This lower flow system may allow for avoidance of complications witnessed with brachial artery AVFs and AVGs, including DASS, high output congestive heart failure, aneurysmal fistula formation, and arm swelling.[30-32] There is no data yet to directly compare the incidence of these complications between pAVFs and surgical AVFs. Furthermore, the Y-shaped pAVF allows for additional sites and increased length for cannulation in comparison to surgical AVFs.[21,22] This may decrease the risk of aneurysm and pseudoaneurysm formation from repeated puncture at the same site.[33] Ultimately, the creation of a pAVF does not prohibit future conversion to a surgical AVF if pAVF failure occurs. Current trials offer the pAVF as a possible alternative to surgical AVF when the creation of a distal, wrist radiocephalic fistula is not possible.

Disadvantages of percutaneous arteriovenous fistulas

Ultimately, none of the trials have had direct comparison of pAVF to surgical AVF outcomes (Table II). Given this, evidence does not support pAVF as a first-line approach in comparison to surgical AVF.[13] Surgical AVFs, if selected properly, have high maturation rates, with a distal radiocephalic maturation rate up to 75–85%.[34,35] Surgical maturation rates are further improved with proximal AVF creations, with approximately 80% for brachial-cephalic fistulas and up to 90% for brachial-basilic fistulas.[35-38]

One disadvantage of pAVF creation could be the cost of the procedure. Cost

of the devices and additional coil embolization may result in increased expenses in comparison to surgical AVF creation. Costs have been estimated to be lower for patients with a WavelinQ™ pAVF in comparison to surgical AVF patients in terms of maintenance.[39,40] However, this cost comparison was performed on an investigation with a lower number of recorded interventions per patient year in comparison to other pAVF studies. (Table VI).[20] Additionally, costs were not collected, but instead estimated for pAVF creation patients.[39,40] More studies are warranted to give an accurate cost comparison between pAVF and surgical AVF.

Additionally, multiple secondary procedures (Table VI) are required for maturation of pAVF for hemodialysis use. pAVF have been referenced as a minimally invasive, outpatient procedure that could help patients avoid "surgical fatigue" associated with dialysis access surgery.[20,41] However, if patient's need multiple interventions, they still may experience a similar fatigue. Furthermore, if patients require open BVT, lipectomy, or basilic vein ligation, they are not being spared an open surgery.

Use of contrast is required with one of the devices for pAVF formation (Table I). This contrast exposure could cause further renal injury to a patient who is CKD V and may result in tunneled catheter use for hemodialysis, with associated increased infection risk.[9,42] Furthermore, in terms of predicting successful pAVF creation and effective maturation for hemodialysis, there are currently no patient factors, which have been established for surgical AVFs,[36] to predict pAVF success or failure. There are inclusion/exclusion criteria based on vessel size for pAVF creation, but it is unknown which patient characteristics will increase or decrease the likelihood of pAVF use.

CONCLUSION

Overall, the percutaneous AVF represents a novel technology for dialysis access creation. High technical success rates are observed in pAVF creation with both devices, given the data is coming from select institutions with highly skilled surgeons and specialists. The formation of a pAVF is applicable in certain situations but is not yet equivalent to that of surgical AVF creation. It is important to understand that multiple secondary procedures could delay maturation of the pAVF and result in the same surgical fatigue experienced by patients with surgical AVFs. Furthermore, patients are not being spared from surgery if superficialization is required. Further studies are warranted to investigate the maturation rates, long-term patencies, and dialysis capabilities of pAVF in comparison to surgical AVF to better understand its utility in dialysis access creation. STI

AUTHORS' DISCLOSURES

The authors have no conflicts of interest to disclose.

REFERENCES

1. Vadakedath S, Kandi V. Dialysis: a review of the mechanisms underlying complications in the management of chronic renal failure. Cureus 2017;9(8):e1603.
2. Blagg CR. The early history of dialysis for chronic renal failure in the United States: a view from Seattle. Am J Kidney Dis 2007;49(3):482–96.
3. Cimino JE, Brescia MJ. Simple venipuncture for hemodialysis. N Engl J Med 1962;267:608–9.
4. Brescia MJ, Cimino JE, Appel K, et al. Chronic hemodialysis using venipuncture and a surgically created arteriovenous fistula. N Engl J Med 1966;275(20): 1089–92.
5. Scribner BH, Buri R, Caner JE, et al. The treatment of chronic uremia by means of intermittent hemodialysis: a preliminary report. Trans Am Soc Artif Intern Organs 1960;6:114–22.
6. Quinton W, Dillard D, Scribner BH. Cannulation of blood vessels for prolonged hemodialysis. Trans Am Soc Artif Intern Organs 1960;6:104–13.
7. Clinical practice guidelines for vascular access. Am J Kidney Dis 2006;48 Suppl 1:S176–247.
8. Allon M. Current management of vascular access. Clin J Am Soc Nephrol 2007;2(4):786–800.
9. Miller LM, Clark E, Dipchand C, et al. Hemodialysis tunneled catheter-related infections. Can J Kidney Health Dis 2016;3:2054358116669129.
10. Dhingra RK, Young EW, Hulbert-Shearon TE, et al. Type of vascular access and mortality in U.S. hemodialysis patients. Kidney Int 2001;60(4):1443–51.
11. Lee T, Barker J, Allon M. Tunneled catheters in hemodialysis patients: reasons and subsequent outcomes. Am J Kidney Dis 2005;46(3):501–8.
12. Malas MB, Canner JK, Hicks CW, et al. Trends in incident hemodialysis access and mortality. JAMA Surg 2015;150(5):441–8.
13. Yan Wee IJ, Yap HY, Tang TY, et al. A systematic review, meta-analysis, and meta-regression of the efficacy and safety of endovascular arteriovenous fistula creation. J Vasc Surg 2020;71(1):309–17 e5.
14. Rajan DK, Ebner A, Desai SB, et al. Percutaneous creation of an arteriovenous fistula for hemodialysis access. J Vasc Interv Radiol 2015;26(4):484–90.
15. Hull JE, Elizondo-Riojas G, Bishop W, et al. Thermal resistance anastomosis device for the percutaneous creation of arteriovenous fistulae for hemodialysis. J Vasc Interv Radiol 2017;28(3):380–7.
16. Lopez-Vargas PA, Craig JC, Gallagher MP, et al. Barriers to timely arteriovenous fistula creation: a study of providers and patients. Am J Kidney Dis 2011; 57(6):873–82.
17. Oliver MJ. The science of fistula maturation. J Am Soc Nephrol 2018;29(11):2607–9.
18. Thamer M, Lee TC, Wasse H, et al. Medicare costs associated with arteriovenous fistulas among US hemodialysis patients. Am J Kidney Dis 2018;72(1): 10–8.
19. Falk A. Maintenance and salvage of arteriovenous fistulas. J Vasc Interv Radiol 2006;17(5):807–13.
20. Lok CE, Rajan DK, Clement J, et al. Endovascular proximal forearm arteriovenous fistula for hemodialysis access: results of the prospective, multicenter novel endovascular access trial (NEAT). Am J Kidney Dis 2017;70(4):486–97.
21. Berland TL, Clement J, Griffin J, et al. Endovascular creation of arteriovenous fistulae for hemodialysis access with a 4 Fr device: clinical experience from the EASE Study. Ann Vasc Surg 2019;60:182–92.
22. Mallios A, Jennings WC, Boura B, et al. Early results of percutaneous arteriovenous fistula creation with the Ellipsys Vascular Access System. J Vasc Surg 2018;68(4):1150–6.
23. Radosa CG, Radosa JC, Weiss N, et al. Endovascular creation of an arteriovenous fistula (endoAVF) for hemodialysis access: first results. Cardiovasc Intervent Radiol 2017;40(10):1545–51.
24. Hull JE, Jennings WC, Cooper RI, et al. The pivotal multicenter trial of ultrasound-guided percutaneous arteriovenous fistula creation for hemodialysis access. J Vasc Interv Radiol 2018;29(2):149–58 e5.
25. Toledo-Pereyra LH, Kyriakides GK, Ma KW, et al. Proximal radial artery-cephalic vein fistula hemodialysis. Arch Surg 1977;112(2):226–7.
26. Gracz KC, Ing TS, Soung LS, et al. Proximal forearm fistula for maintenance hemodialysis. Kidney Int 1977;11(1):71–5.
27. Mallios A, Beathard GA, Jennings WC. Early cannulation of percutaneously created arteriovenous hemodialysis fistulae. J Vasc Access 2019:1129729819892796.
28. Beathard GA, Litchfield T, Jennings WC. Two-year cumulative patency of endovascular arteriovenous fistula. J Vasc Access 2020;21(3):350–6.
29. Mallios A, Bourquelot P, Franco G, et al. Mid-term results of percutaneous arteriovenous fistula creation with the Ellipsys vascular access system, technical recommendations and an algorithm for maintenance. J Vasc Surg 2020;S0741–5214(20):30476–6.
30. Leake AE, Winger DG, Leers SA, et al. Management and outcomes of dialysis access-associated steal syndrome. J Vasc Surg 2015;61(3):754–60.
31. MacRae JM, Pandeya S, Humen DP, et al. Arteriovenous fistula-associated high-output cardiac failure: a review of mechanisms. Am J Kidney Dis 2004;43(5): e17–22.
32. Al-Jaishi AA, Liu AR, Lok CE, et al. Complications of the arteriovenous fistula: a systematic review. J Am Soc Nephrol 2017;28(6):1839–50.
33. Mudoni A, Cornacchiari M, Gallieni M, et al. Aneurysms and pseudoaneurysms in dialysis access. Clin Kidney J 2015;8(4):363–7.
34. Wehrli H, Chenevard R, Zaruba K. [Surgical experiences with the arteriovenous hemodialysis shunt (1970-1988)]. Helv Chir Acta 1989;56(4):621–7.
35. Hakaim AG, Nalbandian M, Scott T. Superior maturation and patency of primary brachiocephalic and transposed basilic vein arteriovenous fistulae in patients with diabetes. J Vasc Surg 1998;27(1):154–7.
36. Siddiqui MA, Ashraff S, Carline T. Maturation of arteriovenous fistula: Analysis of key factors. Kidney Res Clin Pract 2017;36(4):318–28.
37. Maya ID, O'Neal JC, Young CJ, et al. Outcomes of brachiocephalic fistulas, transposed brachiobasilic fistulas, and upper arm grafts. Clin J Am Soc Nephrol 2009;4(1):86–92.
38. Oliver MJ, McCann RL, Indridason OS, et al. Comparison of transposed brachiobasilic fistulas to upper arm grafts and brachiocephalic fistulas. Kidney Int 2001; 60(4):1532–9.
39. Yang S, Lok C, Arnold R, et al. Comparison of post-creation procedures and costs between surgical and an endovascular approach to arteriovenous fistula creation. J Vasc Access 2017;18(Suppl. 2):8–14.
40. Arnold RJG, Han Y, Balakrishnan R, et al. Comparison between surgical and endovascular hemodialysis arteriovenous fistula interventions and associated costs. J Vasc Interv Radiol 2018;29(11):1558–66 e2.
41. Chaudhry M, Bhola C, Joarder M, et al. Seeing eye to eye: the key to reducing catheter use. J Vasc Access 2011;12(2):120–6.
42. Faggioni M, Mehran R. Preventing contrast-induced renal failure: a guide. Interv Cardiol 2016;11(2): 98–104.